

Diagnosis & Treatment Approaches to Gallbladder Volvulus: Review

¹Eyad Saleem j. Alharbi, ²Jamal Sharaf Alzahrani, ³Yousef Mohammad Howssawi, ⁴Ahmad Zuhair Mashat, ⁵Abdulhamid Talal Abdulhamid Alghamdi, ⁶Mohammed Talal Alghamdi, ⁷Mohammad Siraj Ahmad Alghamdi, ⁸Ohoud Aid Alsefri, ⁹Mohammed Hassan Alharthi, ¹⁰Ahmed Saeed S. Banheem, ¹¹Abdullah Khalid Alghamdi

Abstract: This review was aim to overview the diagnostic methods of gallbladder volvulus, as well as the surgical treatment approaches. We conducted a literature search among electronic databases PubMed (National Library of Medicine) using the keywords “gallbladder volvulus” and “gallbladder torsion” together with “diagnosis” and “treatment” up to December 2016, for more identifying case reports discussing the same diagnosis and treatment approaches (surgical treatment) of gallbladder volvulus. Gallbladder volvulus is a rare condition that requires an astute clinician with a heightened index of suspicion and low threshold for carrying out emergent cholecystectomy. This condition must be believed in elderly patients presenting with Right Upper Quadrant pain whose scientific course and signs are refractory to antibiotic treatment and fluid resuscitation. Diagnosis will remain challenging despite improving innovation, but recognition of the common presentation explained herein can result in precise preoperative diagnosis. Gallbladder volvulus mandates emergent cholecystectomy, to avoid visceral perforation, bilious peritonitis, and hemodynamic instability.

Keywords: Diagnosis & Treatment Approaches, Gallbladder volvulus mandates.

1. INTRODUCTION

Gallbladder volvulus or torsion happens when the gallbladder rotates either counterclockwise or clockwise around its mesentery along the axis of the cystic duct and cystic artery causing complete blockage of blood circulation and biliary drain resulting in severe gangrenous cholecystitis ⁽¹⁾. This condition is exceptionally rare; it occurs in less than 0.1% patients who undergo urgent cholecystectomies for assumed acute cholecystitis ⁽²⁾. The incidence of gallbladder volvulus increases with age and peaks in subjects between sixty and eighty years of age. It is more common in females, with a woman: male ratio of 3-4: 1 ⁽³⁾.

It provides as acute abdominal area and typically leads to significant morbidity due to the delay in medical diagnosis and surgical treatment. Since first reported by Wendel in 1898 as a "floating gallbladder," more than five hundred cases have actually been reported in the literature with an occurrence of roughly 1 in 365,000 healthcare facility admissions ^(3,4). With prompt surgical intervention, the potential for gallbladder gangrene and perforation can be avoided and an excellent prognosis is achieved ^(2,5,6). The etiology of gallbladder torsion is unidentified. Anatomic anomalies, such as an abnormally long mesentery or irregular fixation of the gallbladder to the liver, can lead to a suspended gallbladder allowing it to freely drift from the liver bed ⁽¹⁾. It is thought to occur more typically in the senior due to the loss of visceral fat, liver atrophy, and increased elasticity that enables the gallbladder to easily hang or "float." Considerable peristaltic movements of the stomach, duodenum, and close-by colon, in addition to mechanical predisposition triggered by kyphoscoliosis, have actually been pointed out in the literature as predisposing factors for gallbladder torsion ^(7,8). When discovered in patients with gallbladder volvulus, gallstones are considered incidental rather than causative. They are only present in 25-- 50% of patients with gallbladder torsion, and therefore they are unlikely to be the underlying etiology ⁽⁸⁾.

Gallbladder torsion diagnosis is generally not made preoperatively, to name a few things, since ultrasound (US) and computerized tomography (CT) findings are not specific however there is a triad that could be utilized in the diagnosis of gallbladder volvulus (**Table 1**)⁽⁷⁾. Laparoscopic cholecystectomy is the actual suggested treatment⁽⁷⁾.

Table 1: Triad of triads used to recognize potential gallbladder volvulus⁽⁷⁾

Appearance	Symptom	Physical examination
Elderly (usually female)	Sudden onset	Nontoxic presentation
Thin habitus	Right upper quadrant pain	Palpable right upper quadrant mass
Spinal deformities	Early emesis	Pulse-temperature discrepancy

This review was aim to overview the diagnostic methods of gallbladder volvulus, as well as the surgical treatment approaches.

2. METHODOLOGY

We conducted a literature search among electronic databases PubMed (National Library of Medicine) using the keywords “gallbladder volvulus” and “gallbladder torsion” together with “diagnosis” and “treatment” up to December 2016, for more identifying case reports discussing the same diagnosis and treatment approaches (surgical treatment) of gallbladder volvulus.

3. RESULTS

• *Diagnosis of gallbladder volvulus:*

In the past, gallbladder torsion was typically detected intraoperatively. Nevertheless, developments in diagnostic imaging as well as the increased use of imaging in the workup of patients with intense abdominal areas have actually caused an increase in preoperative diagnosis⁽⁹⁾. Ultrasonography and computed tomography are the primary imaging modalities utilized for diagnosis, although they are frequently nonspecific⁽¹⁰⁾. These imaging approaches might expose a floating gallbladder without stones, non-adherent to the liver bed, and outside of the normal structural fossa⁽¹⁾. Previous reports have determined computed tomography requirements for recognizing gallbladder torsion consisting of (a) fluid collection in between the gallbladder and its fossa, (b) the existence of horizontal rather than vertical axis of the gallbladder, (c) the presence of a cystic duct situated on the best side of the gallbladder, and (d) the "whirl sign" of a twisted cystic artery with median deviation of the extrahepatic bile duct⁽¹¹⁾. We identified a very important study⁽⁷⁾ reporting female patients went into diagnostic procedures for gallbladder volvulus and it showed, that the physical examination revealed regular essential signs, moderate dehydration, typical heart sounds without any whisperings, and normal breath sounds on auscultation. The abdomen showed tenderness, pain with palpation on the right upper quadrant, no rebound, normal bowel sounds, lack of Murphy's sign, best costovertebral angle tenderness, and the rectal evaluation was regular. Blood lab tests and an ultrasound were asked for. Laboratory results were the following: leucocytes 20,300, Hb 14.5 g/dL, hematocrit 43%, platelets 202,000, bands 9%, urea 42.8 mg/dL, glucose 110 mg/dL, creatinine 0.8 mg/ dL, Na 139 mmol/L, potassium 4.0 mmol/L, and chloride 103 mmol/L.

The stomach ultrasound (US) revealed severe lithiasic cholecystitis with dilation of intra- and extrahepatic biliary ducts, main bile duct of 9 mm, gallbladder measuring 11.5 cm × 4.8 cm × 7.3 cm, with thickened wall measuring 5 mm to 8.2 mm in the neck, the existence of mobile hyperechogenic images compatible with stones and perivesicular collection (**Figure 1**)⁽⁷⁾. An abdominal CT showed an ovoid image determining 11 cm × 7 cm with uneven thickening of the wall with low-density filling and an ovoid image in the interior measuring 2 cm in diameter, suggesting the presence of a stone (**Figure 2**)⁽⁷⁾. With these findings, acute cholecystitis was believed. The patient went to the OR for laparoscopic cholecystectomy; however, during surgical treatment a totally free lethal gallbladder with a 360 ° counterclockwise torsion in its mesentery was found, and the diagnosis of gallbladder torsion was made. Laparoscopic detorsion and cholecystectomy were performed by clipping and cutting the cystic duct and the cystic artery without issues (**Figure 3**)⁽⁷⁾. A transsurgical cholangiogram revealed no changes. A Jackson-Pratt drain was left in place. The pathological examination of the specimen exposed a 15-cm × 13-cm × 0.4-cm gallbladder with a 0.3-cm wall and the presence of 2 cholesterol calculi determining 2 cm each⁽⁷⁾. Severe cholecystitis with transmural hemorrhagic coagulative necrosis and cholecystolithiasis was reported. The patient was released 5 days later on⁽⁷⁾.

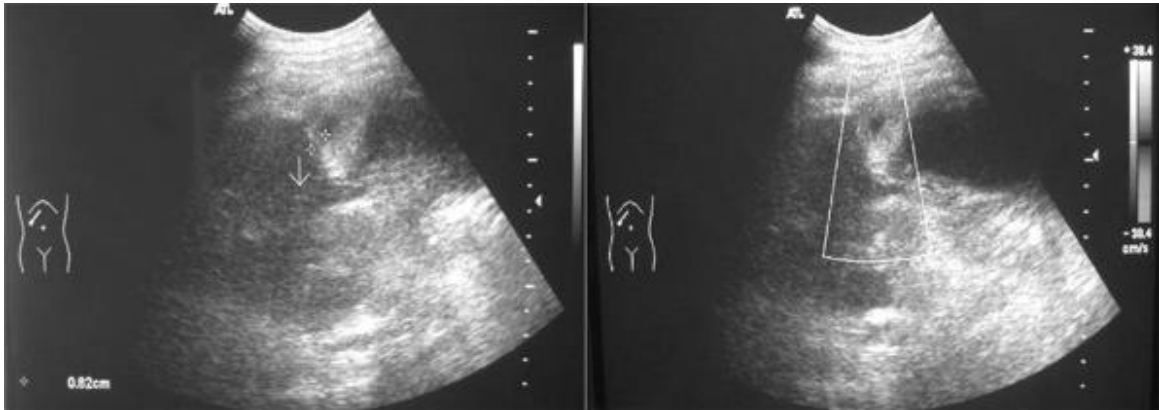


Figure1: Abdominal ultrasound showing the gallbladder with thickened wall and a hyperechoic image suggesting the torsed mesentery. The US Doppler shows no flow within the gallbladder. ⁽⁷⁾

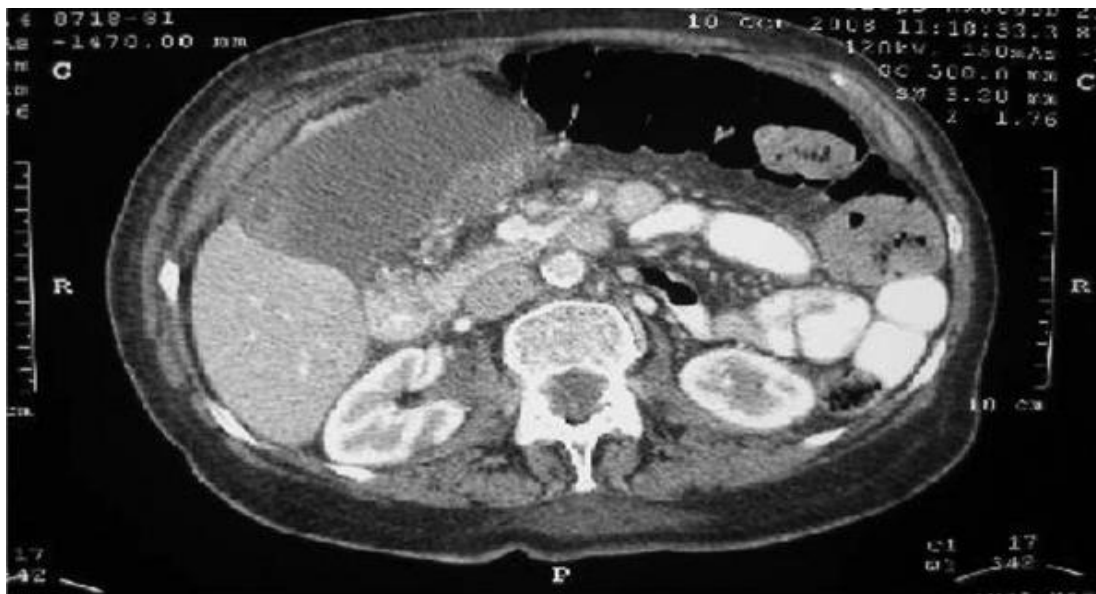

Figure 2: Abdominal computed tomographic scan showing an enlarged gallbladder with asymmetric thickening of the wall with a low-density filling. ⁽⁷⁾

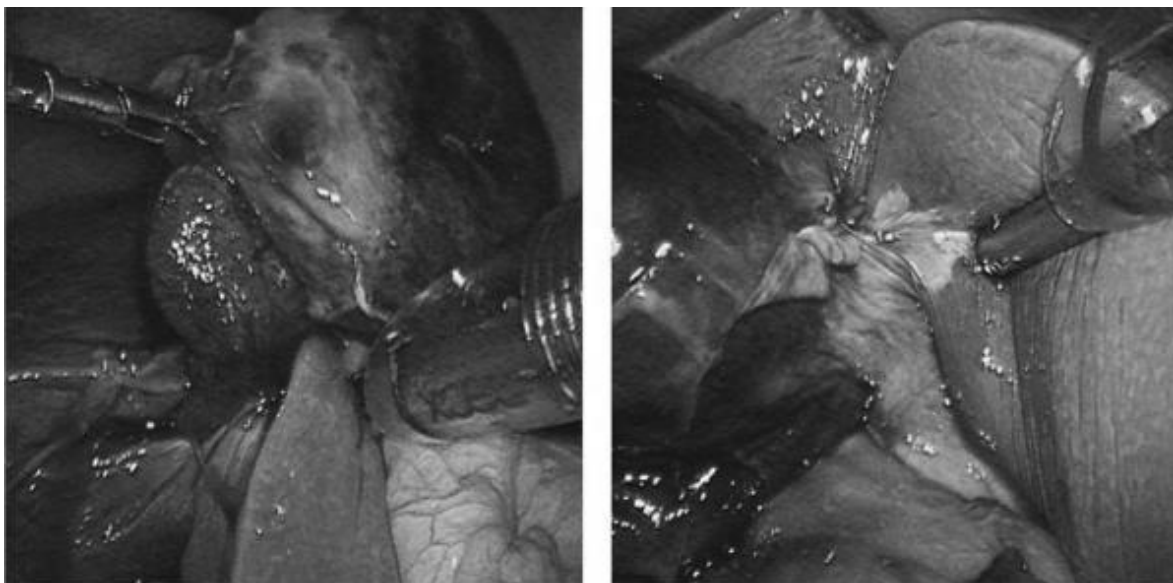


Figure 3: Necrotic floating gallbladder found at laparoscopy. Free necrotic gallbladder with a 360° counterclockwise torsion in its mesentery. ⁽⁷⁾

The clinical presentation can have nonspecific symptoms and signs. For that reason, the medical diagnosis is normally not made preoperatively. In the incomplete torsion, the patient may provide with signs suitable with biliary colic, while those with total torsion will have a history of abrupt beginning of extreme right upper quadrant pain and vomiting. In some patients, a palpable gallbladder can be discovered on assessment⁽¹²⁾. Lau et al⁽¹³⁾ explained 3 triads for the medical diagnosis of gallbladder torsion. These triads consider signs, such as short history, stomach pain, and early vomiting; physical indications consisting of abdominal mass, lack of toxemia, and pulse rate-temperature inconsistency; and lastly, patient's qualities like thin complexion, old age, and deformation of the spine. Normally the patient is detected with cholecystitis, but the absence of jaundice and fever in addition to the bad response to antibiotics can assist the doctor discard this diagnosis⁽¹⁴⁾. Laboratory tests can show high leucocytes and normal hepatic function tests. Imaging studies like stomach US and CT are not specific. US shows a large gallbladder outside its anatomical fossa with a thickened wall surrounded by fluid. Sometimes, gallstones can likewise be visualized⁽¹⁵⁾. When using color doppler to the US, circulation is absent in the torsed gallbladder. When color circulation is present, the diagnosis of gallbladder torsion can be rejected and intense cholecystitis must be presumed⁽¹⁶⁾. CT findings consist of the presence of fluid in between the gall-bladder and liver, a horizontal personality of the gall-bladder, improvement of the cystic duct localized on the right side of the gallbladder, and images suggesting edema and thickening of the wall⁽¹⁷⁾. A distended gall-bladder, much like a bowel loop with a high attenuation circular structure to the right of the gallbladder, is considered a specific sign of gallbladder torsion by Merine et al⁽¹⁸⁾. The US and CT findings in our case coincide with the ones explained for gallbladder torsion; nevertheless, it was not possible to develop the diagnosis preoperatively.

➤ Surgical treatment of gallbladder volvulus:

Treatment is surgical derotation and cholecystectomy. In the past, open treatments were performed. With experience in laparoscopic cholecystectomy, laparoscopic derotation and cholecystectomy will end up being the preferred method. Gallbladder decompression and detorsion prior to cholecystectomy are handy techniques to avoid bile duct injury^(1,7) if treated laparoscopically.

A case report study⁽¹⁹⁾ was determined and they have actually carried out laparoscopic cholecystectomy for 83-year-old female that was detected with gallbladder volvulus. On laparoscopic examination, the gallbladder was found to be free-floating, twisted at its junction with the cystic duct and artery at 270 degrees, and gangrenous (**Figure 4**)⁽¹⁹⁾. After detorsion and decompression by needle suction, a watershed line along the volvulus was noted at the junction of the cystic artery and duct. There was no intraoperative or postoperative complication. The patient's postoperative course was uneventful and she was discharged on post-operative day 2. Pathological examination exposed gallbladder strangulation with congestion, mucosal necrosis and fibrin thrombi in vessels. A follow-up at the outpatient department one week after surgical treatment revealed that the patient was in good condition⁽¹⁹⁾.

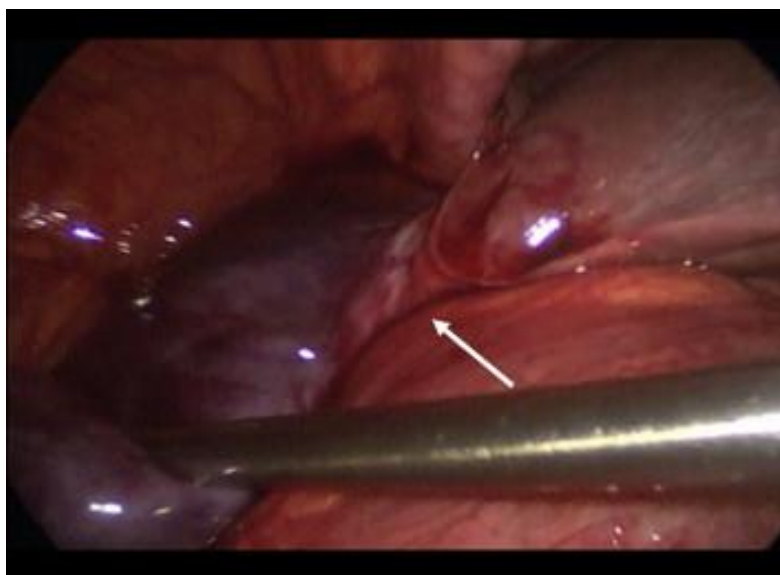


Figure 4: White arrow indicates twisted gallbladder along adhesion to liver bed and lengthened cystic duct.

Another case report study⁽²⁰⁾ was included which including 9-year-old boy complained of stomach pain, laboratory outcomes showed WBC count was likewise within the typical range. On days 2 and 3, a palpable mass appeared in the

ideal hypochondrium and really mild rebound tenderness was observed. Since cholecystitis, gallbladder volvulus, choledochal cyst and bile duct obstruction due to a biliary tract stone were thought about as the differential medical diagnosis, MRI, MR cholangiopancreatography (MRCP) and CT were duplicated. The gallbladder body wall was considerably thickened, did not attach to the inferior surface of the liver and was freely suspended. Beak-like stenoses were spotted in the gallbladder neck and body. These 2 "beaks" were arranged face-to-face. These findings were extremely easily noticeable in the coronal view of the CT and MRI. The thickened wall of the gallbladder body was of slightly high-signal in T1-weighted images and low-signal in T2-weighted images on the MR study. The thickened wall of the gallbladder body was inadequately boosted in contrast-enhanced CT. No choledocholithiasis was spotted. A medical diagnosis of gallbladder volvulus was established. On Day 4 after admission, laparoscopy was carried out. The gallbladder was covered with an inflamed higher omentum. Just the cystic duct was repaired with mesentery; the gallbladder body was not fixed to the inferior surface of the liver and hung free. The gallbladder appeared gangrenous with > 180 ° counterclockwise torsion. Laparoscopic cholecystectomy was carried out. His postoperative scientific course was uneventful and he was discharged on the fourth postoperative day⁽²⁰⁾.

Laparoscopic cholecystectomy has actually also been reported to be reliable for diagnosis and treatment due to the fact that it can supply direct visible information of the gallbladder, which leads to conclusive medical diagnosis. Furthermore, this technique can provide very little intrusive treatment because the gallbladder is usually floating and its separation from the liver bed can be performed easily^(21,22,23).

4. CONCLUSION

Gallbladder volvulus is a rare condition that requires an astute clinician with a heightened index of suspicion and low threshold for carrying out emergent cholecystectomy. This condition must be believed in elderly patients presenting with Right Upper Quadrant pain whose scientific course and signs are refractory to antibiotic treatment and fluid resuscitation. Diagnosis will remain challenging despite improving innovation, but recognition of the common presentation explained herein can result in precise preoperative diagnosis. Gallbladder volvulus mandates emergent cholecystectomy, to avoid visceral perforation, bilious peritonitis, and hemodynamic instability.

REFERENCES

- [1] Mouawad N. J., Crofts B., Streu R., Desrochers R., Kimball B. C. Acute gallbladder torsion—a continued pre-operative diagnostic dilemma. *World Journal of Emergency Surgery*. 2011;6(1, article 13) doi: 10.1186/1749-7922-6-13.
- [2] Nakao A., Matsuda T., Funabiki S., et al. Gallbladder torsion: case report and review of 245 cases reported in the Japanese literature. *Journal of Hepato-Biliary-Pancreatic Surgery*. 1999;6(4):418–421. doi: 10.1007/s005340050143.
- [3] Reilly D. J., Kalogeropoulos G., Thiruchelvam D. Torsion of the gallbladder: a systematic review. *HPB*. 2012; 14(10):669–672. doi: 10.1111/j.1477-2574.2012.00513.x.
- [4] Wendel A. V. VI. A case of floating gall-bladder and kidney complicated by cholelithiasis, with perforation of the gall-bladder. *Annals of Surgery*. 1898;27(2):199–202.
- [5] Kim S. Y., Moore J. T. Volvulus of the gallbladder: laparoscopic detorsion and removal. *Surgical Endoscopy*. 2003;17(11):p. 1849.
- [6] Amarillo H. A., Pirchi E. D., Mihura M. E. Complete gallbladder and cystic pedicle torsion. Laparoscopic diagnosis and treatment. *Surgical Endoscopy*. 2003;17(5):832–833. doi: 10.1007/s00464-002-4528-3.
- [7] Garcavilla P. C., Alvarez J. F., Uzqueda G. V. Diagnosis and laparoscopic approach to gallbladder torsion and cholelithiasis. *Journal of the Society of Laparoendoscopic Surgeons*. 2010;14(1):147–151. doi: 10.4293/108680810x12674612765588.
- [8] Stieber A. C., Bauer J. J. Volvulus of the gallbladder. *The American Journal of Gastroenterology*. 1983;78(2):96–98.
- [9] Hinoshita E., Nishizaki T., Wakasugi K., et al. Pre-operative imaging can diagnose torsion of the gallbladder: report of a case. *Hepato-Gastroenterology*. 1999; 46(28):2212–2215.

- [10] Boonstra E. A., van Etten B., Prins T. R., Sieders E., van Leeuwen B. L. Torsion of the gallbladder. *Journal of Gastrointestinal Surgery*. 2012;16(4):882–884. doi: 10.1007/s11605-011-1712-6.
- [11] Tajima Y., Tsuneoka N., Kuroki T., Kanematsu T. Gallbladder torsion showing a ‘whirl sign’ on a multidetector computed tomography scan. *American Journal of Surgery*. 2009;197(1):e9–e10. doi: 10.1016/j.amjsurg. 2008. 01. 030.
- [12] Ijaz S, Sritharan K, Russell N, Dar M, Bhatti T, Ormiston M. Torsion of the gallbladder: a case report. *J Med Case Reports*. 2008;2:237–239.
- [13] Lau WY, Fan ST, Wong SH. Acute torsion of the gallbladder in the aged: a re-emphasis on clinical diagnosis. *Aust N Z J Surg*. 1982;52:492–494.
- [14] Reddy PK, Muralidharam M, Venkatasubram R, et al. Laparoscopic derotation and cholecystectomy for torsion gallbladder. *JLS*. 2005;9(2):238–240.
- [15] Yeh H, Weiss M, Green C. Torsion of the gallbladder: the ultrasonographic diagnosis of the gallbladder torsion. *J Ultra-sound Med*. 1989;5:296–298
- [16] Ralls PW. The gallbladder and bile ducts. In: Jeffrey RB Jr., editor. , ed. *CT and sonography of the acute abdomen*. 2nd ed. Philadelphia: Lippincott-Raven; 1996;74–121
- [17] Kitagawa H, Nakada K, Enami T, et al. Two cases of torsion of the gallbladder diagnosed preoperatively. *J Pediatr Surg*. 1997;32(11):1567–1569
- [18] Merine D, Meziane M, Fishman EK. CT diagnosis of gallbladder torsion. *J Comput Assist Tomogr*. 1987;11:712–713
- [19] D.M. Schroder, D.A. Cusumano 3rd. Laparoscopic cholecystectomy for gallbladder torsion. *Surg Laparosc Endosc*, 5 (1995), pp. 330–334.
- [20] Inoue S, Odaka A, Hashimoto D, Tamura M, Osada H. Gallbladder volvulus in a child with mild clinical presentation. *Pediatr Radiol*. 2011 Jan;41(1):113-6. doi: 10.1007/s00247-010-1753-0.
- [21] Kimura T, Yonekura T, Yamauchi K et al (2008) Laparoscopic treatment of gallbladder volvulus: a pediatric case report and literature review. *J Laparoendosc Adv Surg Tech A* 18:330–334.
- [22] Hamada T, Tajima Y, Yamaguchi J et al (2009) Torsion of the gallbladder in a 3-year-old infant. *J Hepatobiliary Pancreat Surg* 16:234–237.
- [23] Matsuda A, Sasajima K, Miyamoto M et al (2009) Laparoscopic treatment for torsion of the gallbladder in a 7-year-old female. *JLS* 13:441–444